



Contents lists available at SciVerse ScienceDirect

Journal of Electromyography and Kinesiology

journal homepage: www.elsevier.com/locate/jelekin

Ultrasound-guided insertion of intramuscular electrodes into suboccipital muscles in the non-human primate

Brian D. Corneil^{a,b,c,d,*}, Samantha C. Goonetilleke^a, Tyler R. Peel^c, Katherine A. Green^a, Ian D. Welch^e

^a Department of Physiology & Pharmacology, University of Western Ontario, London, Ontario, Canada

^b Department of Psychology, University of Western Ontario, London, Ontario, Canada

^c Graduate Program in Neuroscience, University of Western Ontario, London, Ontario, Canada

^d Robarts Research Institute, London, Ontario, Canada

^e Department of Animal Care and Veterinary Services, University of Western Ontario, London, Ontario, Canada

ARTICLE INFO

Article history:

Received 8 December 2011

Received in revised form 11 January 2012

Accepted 21 February 2012

Keywords:

Motor control

Neck muscles

Electromyography

Ultrasonography

ABSTRACT

The head–neck system is highly complex from a biomechanical and musculoskeletal perspective. Currently, the options for recording the recruitment of deep neck muscles in experimental animals are limited to chronic approaches requiring permanent implantation of electromyographic electrodes. Here, we describe a method for targeting deep muscles of the dorsal neck in non-human primates with intramuscular electrodes that are inserted acutely. Electrode insertion is guided by ultrasonography, which is necessary to ensure placement of the electrode in the target muscle. To confirm electrode placement, we delivered threshold electrical stimulation through the intramuscular electrode and visualized the muscle twitch. In one animal, we also compared recordings obtained from acutely- and chronically-implanted electrodes. This method increases the options for accessing deep neck muscles, and hence could be used in experiments for which the invasive surgery inherent to a chronic implant is not appropriate. This method could also be extended to the injection of pharmacological agents or anatomical tracers into specific neck muscles.

© 2012 Elsevier Ltd. All rights reserved.

1. Introduction

The dorsal suboccipital muscles in the upper neck (shown in Fig. 1 for monkeys) present an interesting target for sensori-motor neuroscience. From a motor perspective, these muscles are targeted by a variety of descending pathways (Isa and Sasaki, 2002; Shinoda et al., 2006) and recruited during even the smallest head movements in cats and monkeys (Corneil et al., 2001; Lestienne et al., 1995; Richmond et al., 1992). Study of suboccipital muscle recruitment can therefore provide insight into the functional signals relayed along these pathways. For example, many aspects of their recruitment in monkeys parallel pre-saccadic activity within the oculomotor system (Corneil et al., 2004, 2008; Rezvani and Corneil, 2008), particularly for horizontal movements given the organization of the cervical spinal column (Graf et al., 1995). From a sensory perspective, these muscles have a very high complement of sensory receptors (Bakker and Richmond, 1982; Cooper and Daniel, 1963; Kulkarni et al., 2001; Richmond et al., 1999b). Afferent inputs from neck muscles are integrated with vestibular inputs throughout the neuraxis [see Angelaki and Cullen (2008) for

review], and contribute to the sense of body-under-head position required for many sensori-motor transformations. Altered or nociceptive afferent input from the upper cervical neck has also been suggested in a variety of musculoskeletal, pain, and equilibrium disorders [see Bogduk and Govind (2009), Falla et al. (2004), and Richmond et al. (2001a) for review].

The dorsal suboccipital muscles are not easily accessed in humans. Although intramuscular recordings have been described (Bexander et al., 2005; Blouin et al., 2007), such an approach is likely limited to healthy and cooperative subjects. Animal models potentiate the pairing of intramuscular approaches with neurophysiological or neuroanatomical techniques that cannot be used in humans. Although the cat traditionally served as the animal model for the control and sensation of head motion, rhesus monkeys have more recently come in to favour, given both the comparatively higher degree of morphological homology with humans, and amenability for training in head-unrestrained tasks (Chapman and Corneil, 2011; McCluskey and Cullen, 2007; Populin, 2006; Richmond et al., 1999a).

Currently, experimental approaches targeting the dorsal suboccipital muscles in animals require a chronic implant. In previous work in the monkey, we have used a dorsal approach to the muscles down the midline raphe, with consequent exposure of numerous muscles, including those in suboccipital region (Corneil et al.,

* Corresponding author. Address: Robarts Research Institute, London, Ontario, Canada N6A 5K8. Tel.: +1 (519) 663 5777x24132; fax: +1 (519) 931 5233.

E-mail address: bcorneil@uwo.ca (B.D. Corneil).

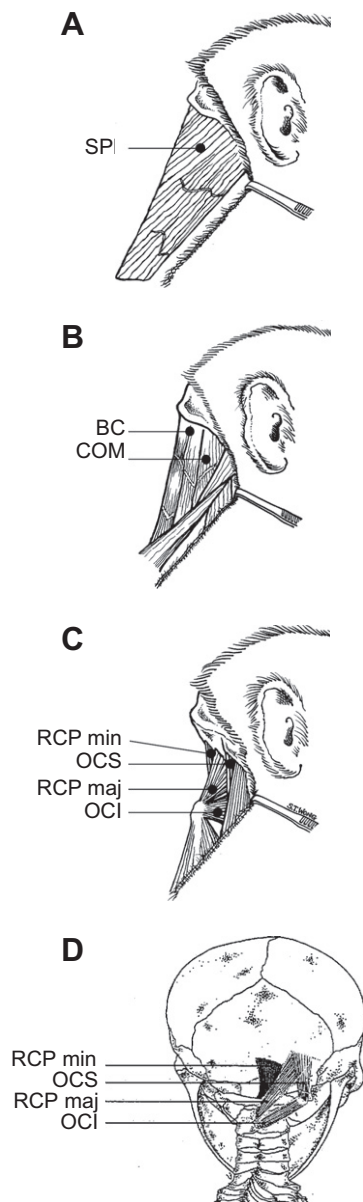


Fig. 1. Anatomical sketches of some of the neck muscles in the upper dorsal neck of the monkey, taken from the right side (A–C; ordered from superficial to deep) or back (D) perspective. SPL = splenius capitis; BC = biventer cervicis; COM = complexus; RCP min = rectus capitis posterior minor; OCS = obliquus capitis superior; RCP maj = rectus capitis posterior major; OCI = obliquus capitis inferior.

2001). While appropriate for certain experiments, such an approach has a number of disadvantages. First, it requires an invasive surgery, risking peri-surgical damage to nerves and vasculature as well as post-surgical complications. Second, because the electrodes are implanted chronically and are fixed in place, it is not feasible to replace them should they fail, nor easily sample different muscle locations within the same experimental animal.

The goal of this paper is to describe an alternative technique for acutely targeting the dorsal suboccipital neck muscles in the monkey. As in humans (Kamibayashi and Richmond, 1998), the muscles of the dorsal neck in the monkey are very complex from an anatomical perspective, with the suboccipital muscles investing the deepest of four layers (Richmond et al., 2001b). We therefore guided the needle insertion of fine-wire electromyographic (EMG) electrodes via ultrasonography, and confirmed localization in the target muscle via ultrasound visualization of muscle twitches evoked by

electrical stimulation through the EMG electrodes. We also compared EMG activity recorded simultaneously from acutely- or chronically-implanted EMG electrodes, and describe a simple sedation/reversal procedure that serves the dual purpose of providing analgesia during electrode insertion, and rapid reversal so that the animal subject can perform behavioural tasks.

2. Experimental apparatus and signal analysis methods

Two male monkeys (*Macaca mulatta*, monkeys D and S) weighing 9.4 and 14.0 kg, respectively were used in this experiment. All surgical and experimental procedures were conducted in accordance with the Canadian Council on Animal Care guidelines on the use of laboratory animals, and approved by the Animal Use Subcommittee of the University of Western Ontario Council on Animal Care. As described elsewhere (Elsley et al., 2007), monkey S had previously undergone a surgery for the chronic implant of bipolar hook EMG electrodes stitched directly in ten neck muscles (including the suboccipital muscles). Electrode leads were tunneled subcutaneously and connected to a connector embedded within a pre-existing cranial acrylic implant. The availability of these chronically-implanted muscles provided an opportunity to simultaneously compare EMG recordings from acutely- or chronically-implanted muscles.

2.1. Ultrasonography

Ultrasound images were obtained using a Medison Sonoace Pico ultrasound machine, using either a linear probe (Probe HL5-9ED; 7.5 MHz, 40 mm) or a curvilinear probe (Probe C4-9ED; 6.5 MHz, 10 mm). Although either probe provided sufficient visualization of the electrode during insertion, the smaller footprint of the curvilinear probe made visualization easier given the angle of approach and curvature of the dorsal neck in relationship to the target muscle. Prior to needle insertion, the target area was shaved and then cleaned with a chlorhexidine skin soap (Hibitane). The skin-probe interface was maintained with isopropyl alcohol instead of ultrasound gel to avoid introducing the gel to subcutaneous tissues.

We describe the insertion of the needle from midline, so that it lies medial relative to the ultrasound probe. This midline approach eases the visualization of the needle's progress through the various muscle layers. We did explore an alternative approach where the needle started lateral to the ultrasound probe, but felt that this approach started too rostrally, since we tried to keep the progress of the needle as parallel as possible to the long axis of the muscle of interest (which, in the case of OCI, runs rostro-lateral from its origin at C2). We note that starting the needle lateral to the ultrasound probe may be an appropriate way of targeting other muscles, and may help avoid a proliferation of fine-wire leads at midline when multiple bilateral insertions are required.

2.2. EMG electrodes, intramuscular stimulation and signal processing

Intramuscular EMG electrodes were obtained commercially from Motion Lab Systems (Baton Rouge, LA), and consisted of bipolar leads (304 series stainless steel, 0.051 mm diameter with green nylon insulation, hooked wires and a 200 mm tail with 2 mm exposed at the insertion) threaded into either a 30 mm, 27 gauge cannula or a 50 mm, 25 gauge cannula. Either cannula was visible under ultrasonography during insertion. The exposed contacts on these electrodes are staggered by ~3 mm, and are bent back over the end of the cannula. Once the cannula reached the appropriate target, it was withdrawn carefully around the electrode lead and discarded.

In both monkeys, the localization of the fine-wire EMG electrodes were confirmed after cannula withdrawal by delivering intramuscular stimulation through the electrodes and visualizing muscle twitches. Bipolar intramuscular stimulation was delivered through a Grass S88 stimulator attached to two PSIU6 stimulus isolation units for the delivery of constant current stimulation. Stimulation consisted of a train of biphasic pulses (each phase 0.3 ms in duration) delivered at a frequency of 33 Hz for 300 ms. Stimulus intensity was decreased to the threshold current associated with the smallest muscle twitch visible under ultrasound (typically between 100 and 200 μ A), and the location of the muscle twitch using the threshold current was deemed to be the location of the electrodes.

EMG recordings were obtained from the intramuscular electrodes inserted into monkey S. A ground electrode, consisting of a disposable self-adhesive Ag/AgCl electrode (Blue Sensor, Run Technologies) was adhered to the subject's clavicle. EMG activity from the acutely inserted electrodes was recorded with a Myopac Jr system (Run Technologies, Laguna Hills, CA; low-pass filter modified to 2 kHz). The EMG data were amplified and sampled as an analog channel into a Plexon Multi-acquisition processor (Plexon Inc., Dallas, TX), alongside EMG activity recorded from the chronically-implanted electrodes, and eye-in-head position signals obtained by an eye-tracking system (ETL-200 Primate Eye Tracker; ISCAN). All analog signals were digitized at 10 kHz at a 12 bit resolution. Offline, the eye position signals were downsampled to 1 kHz, and the EMG signals were corrected for the DC offset, full-wave rectified, and then bin-integrated into 1 ms bins, as described previously (Elsley et al., 2007). Our assessment of neck muscle recruitment took advantage of the well-known correlation between the recruitment of our targeted suboccipital neck muscle and ipsilateral horizontal eye-in-head position (André-Deshays et al., 1988; Corneil et al., 2002).

2.3. Sedation and reversal

In monkey S, electrode insertion was performed while the animal was sedated in a primate chair. The rationale here is to insert the electrodes under sedation, and then reverse the sedation so that the animal can perform a behavioural task. Sedation was first induced by an intramuscular injection of Ketamine (1.5 mg/kg) and Medetomidine (0.0125 mg/kg), followed by subcutaneous injections of Atropine (0.05 mg/kg) and Metacam (0.2 mg/kg). The animal's head was then restrained via an implanted head post. After bilateral insertion of intramuscular electrodes into the right and left suboccipital region, sedation was reversed by an intramuscular injection of Atipamezole (0.0125 mg/kg). The monkey was then given 30 min to recover.

3. Demonstration and evaluation of insertion technique

3.1. Neck muscle anatomy

The morphometry of monkey neck muscles have been described previously (Richmond et al., 2001b), and will be briefly reviewed here to better clarify how these muscles appear under ultrasound. The largest and most superficial neck muscles link the skull and cervical vertebrae to the shoulder girdle. Muscles in this layer include trapezius (TRAP), sternocleidomastoid (SCM), and rhomboideus (RH). Intermediate layers consist primarily of long muscles that link the skull to the lower cervical and thoracic vertebrae. Muscles in this layer include splenius capitis (SPL; Fig. 1A) and semispinalis capitis (Fig. 1B), which in monkeys are composed of the muscles biventer cervicis (BC) and complexus (COM). The deepest muscles, which include the suboccipital muscles, connect the skull to upper cervical vertebrae, or interconnect vertebral bones (Fig. 1C).

The dorsal suboccipital muscles, also shown in Fig. 1D in another view, consist of two muscle groups: the obliquus capitis group, and the rectus capitis group. Obliquus capitis inferior (OCI) has the most laterally-oriented fibre angle within this group of muscles, running obliquely from the spinous process of C2 (the axis) to the transverse process of C1 (the atlas). Obliquus capitis superior (OCS) runs from the rostral aspect of the C1 transverse process to the lateral occiput. Rectus capitis posterior major (RCP maj) spans from the lateral occiput (medial to OCS) to the spinous process of C2, running at an angle of $\sim 25^\circ$ with respect to body midline. Rectus capitis posterior minor (RCP min) runs deep and medial to RCP maj, spanning from the medial occiput to the dorsal arch of the axis.

3.2. Localization and appearance of dorsal suboccipital region with ultrasonography

Under ultrasonography, the dorsal region of the upper neck has a distinctive appearance that aids the identification of the suboccipital muscles. We have found that a beneficial approach to this region is to first locate the spinous process of C2, as it is the first prominent midline landmark caudal to the occiput. To do this, we recommend first orienting the ultrasound probe transversely on the back of the skull, just rostral to the soft tissues of the neck, and then translating the probe caudally on midline. The spinous process of C2 soon becomes apparent. The transverse processes of C1 and C2 can also be seen with this approach.

Once the bony landmarks have been identified, the muscles can be easily differentiated, as can the various muscle layers. The most superficial muscle visible with this approach is the cranial slip of TRAP; at this part of the neck, the muscle is very thin and the thickness of this muscle belly will not change as the probe is translated laterally. The muscle beneath TRAP is SPL, which appears very slim medially but thickens more laterally. The muscle beneath SPL is BC, which is considerably thicker than either TRAP or SPL at this level. The suboccipital muscles lie underneath BC.

3.3. Insertion of intramuscular electrode in an anesthetized subject, and anatomical verification via intramuscular stimulation

We now describe the insertion of a device specifically into OCI, first in a subject (monkey D) who was anesthetized via our standard protocol (Elsley et al., 2007) and placed prone on an operating table. Once the bony landmarks and muscle layers have been identified as above with a midline probe position, we recommend translating the probe laterally and rotating it slightly (counterclockwise for right-OCI) in order to visualize the long axis of this muscle (see depiction of probe location in Fig. 2A), keeping the C2 spinous process in view. This view of the dorsal neck is shown in Fig. 2B and C, with reference to some of the anatomical landmarks mentioned above.

Once the probe has been appropriately positioned, we proceeded with insertion of the intramuscular electrode. Fig. 3 shows a 20 s video of the insertion of an intramuscular EMG electrode into right-OCI, with the probe positioned as in Fig. 2. Note from this video how the course of the needle begins from midline, and that the cannula housing the EMG electrode is easily visualized. Once the cannula reaches the appropriate depth, it is withdrawn around the electrode, which stays behind in the muscle because the electrode was bent back over the cannula. The bared ends of the EMG wires are actually visible in Fig. 2B, and can be seen to reside in the desired location.

During the insertion, it is important that the cannula takes the appropriate angle to the muscle; too shallow risks missing the desired target laterally, and too steep risks abutting the cannula against the spinous process of C2. We have found it occasionally necessary to adjust the angle of the cannula after insertion through

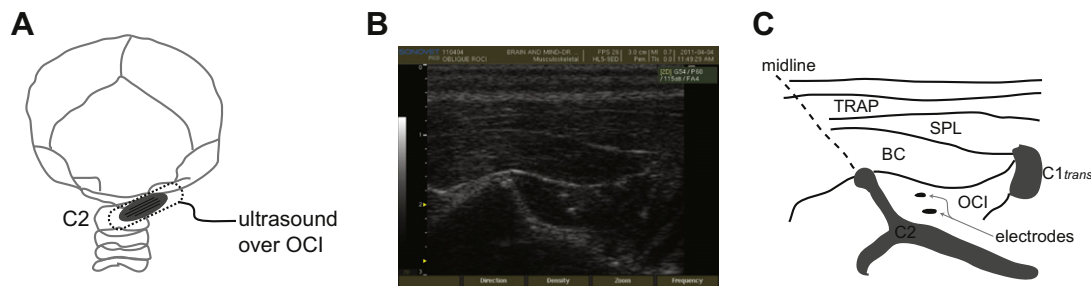


Fig. 2. Ultrasonographic appearance of upper dorsal neck in the monkey. (A) Anatomical sketch depicting position of ultrasound probe over right-OCI. Ultrasound picture (B) and line drawing of ultrasound picture (C), emphasizing anatomical landmarks. TRAP = trapezius; C1trans = transverse process of C1.

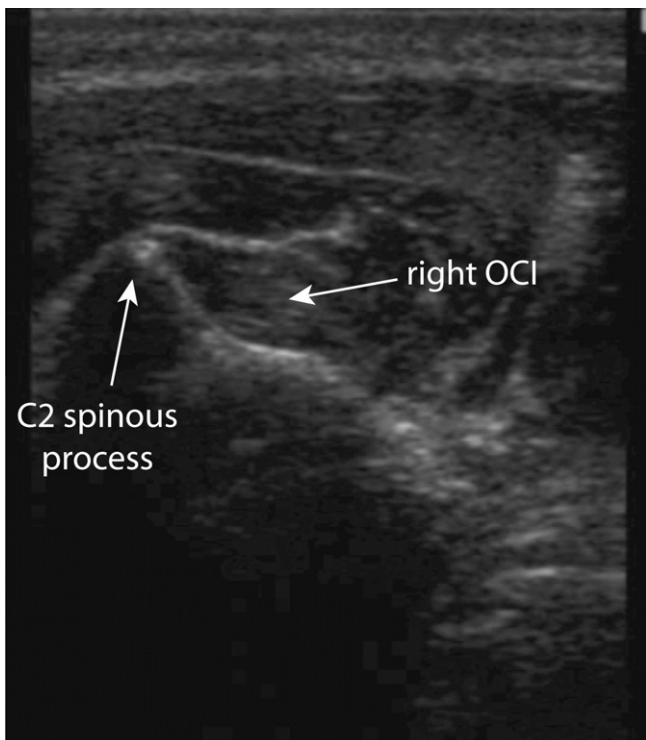


Fig. 3. Still from movie 1. This movie shows the insertion of an intramuscular electrode into the right-OCI muscle of monkey D, using the linear ultrasound probe. During this video, the cannula carrying the electrode will enter from the top-left portion of the image, and be advanced until it lies within the target muscle.

the skin. Because the fine-wire electrode can slide freely within the cannula, it is important during such adjustments to ensure that the electrode is stabilized relative to the cannula; this can be done by simply pinching the electrode lead to the top part of the cannula. Failure to do so can effectively stitch the electrode into other muscle bellies.

Although the electrode contacts can be visualized in the picture shown in Fig. 2B, it was not always possible to do so. We therefore used intramuscular stimulation to visualize the muscle twitch associated with the lowest stimulation current. These muscle twitches can be seen in Fig. 4, with a higher or lower stimulation current causing a greater or more limited volume of tissue to twitch, respectively.

3.4. Insertion in sedated subject and physiological verification upon reversal

We now describe a similar type of insertion in a moderately-sedated subject (monkey S), seated with the head restrained in a primate chair. This type of insertion would be appropriate for

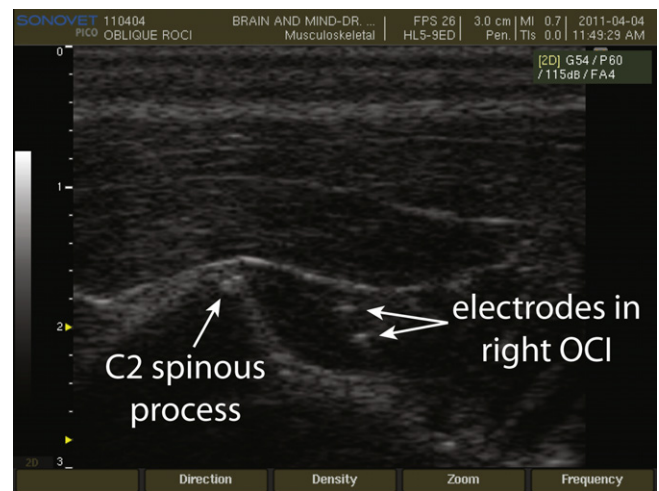


Fig. 4. Still from movie 2. This movie shows muscle twitches evoked by a relatively high (200 μ A) or low (100 μ A) amount of current delivered through the intramuscular electrode. Note the small volume of tissue excited by stimulation at the lower current, confirming electrode placement.

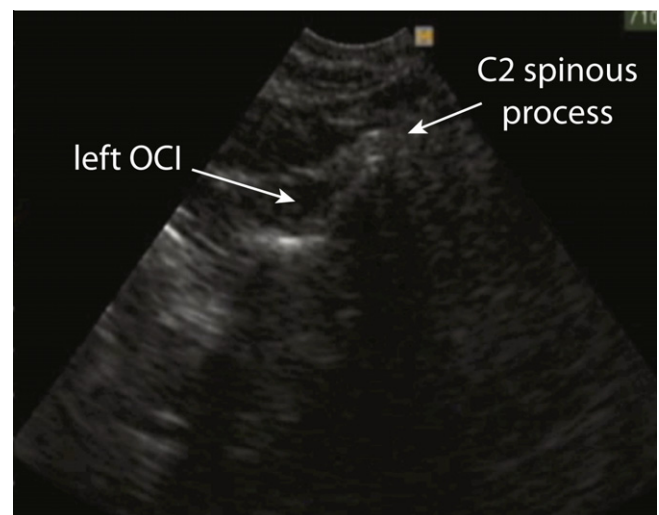


Fig. 5. Still from movie 3. The first clip in this movie shows the insertion of an intramuscular electrode into the left-OCI muscle of monkey S, using the curvilinear ultrasound probe. The second clip shows the muscle twitches evoked by threshold stimulation.

experiments pairing neck EMG recordings with neurophysiological approaches in an awake, behaving preparation. We also display the appearance of the upper dorsal neck with a curvilinear probe,

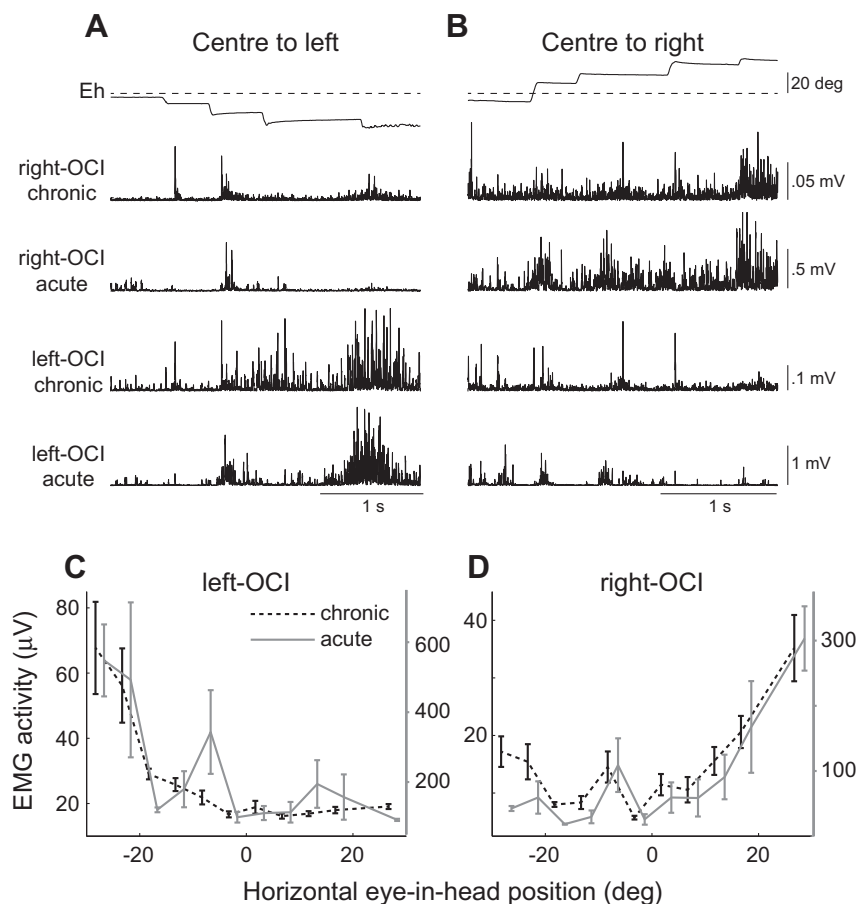


Fig. 6. Comparison of tonic eye-position signal recorded from OCI implanted either chronically or acutely. (A, B) Examples of changes in OCI recruitment with different tonic horizontal eye-in-head positions (Eh; up denotes right; horizontal dashed line shows straight ahead). (C, D) Relationship between OCI recruitment and tonic eye-in-head position, averaged across 110 intervals of stable fixation recorded during a three minute interval. For both left and right-OCI, recruitment is recorded from either chronically-implanted (black, dashed lines, left abscissa) or acutely-implanted (gray, solid lines, right abscissa) electrodes. Recruitment has been binned into 5 deg bins, with the lines offset slightly to ease viewing. Error bars represent SE.

which is easier to use given its smaller contact area on the surface of the neck. Insertion of an electrode into left-OCI, and muscle twitches evoked by a lower stimulation current are shown in the movie in Fig. 5.

After bilateral insertion of intramuscular EMG electrodes into OCI, the sedation was reversed. Once the animal had fully recovered, we simultaneously recorded neck EMG activity from both the acutely-inserted EMG electrodes, and from the chronically-inserted EMG electrodes. In Fig. 6, we show how the recruitment of these muscles co-varies with horizontal eye-in-head position, as described previously in monkeys (Corneil et al., 2002). Fig. 6A and B show sequences where the monkey looks from centre to the left, or from centre to the right, along with bilateral OCI activity recorded from both chronic electrodes implanted in a previous surgery, and from the acutely-inserted intramuscular electrodes. Note how OCI recruitment increases with increasing ipsilateral eye positions (i.e., left-OCI activity increases for more leftward eye-in-head positions), regardless of the type of EMG electrode. Fig. 6C and D plot left or right OCI recruitment as a function of tonic eye position extracted over 110 intervals of stable fixation, respectively; again, note the correspondence between recruitment and ipsilateral eye position, regardless of electrode type.

4. Discussion

We have demonstrated an acute approach for the insertion of intramuscular electrodes into a target muscle within the dorsal

suboccipital region. The value of this approach is that it increases the options for accessing this region, and hence would be suitable for experiments for which the invasive surgery or fixed electrode placement inherent to a chronic implant are not appropriate. Moreover, this technique could be extended to other muscles in the primate neck, potentially providing a comparative dataset to similar recordings made from deep muscles in humans (Bexander et al., 2005; Blouin et al., 2007; Falla et al., 2003, 2006) that are inaccessible to surface recording techniques (Mayoux-Benhamou et al., 1995). Primate neck muscles display a high degree of structural and histochemical complexity (Richmond et al., 2001b), and the distribution of different fibre types throughout a muscle is far from homogenous, even within a small muscle such as OCI (Richmond et al., 1999b). Sequential insertion of intramuscular electrodes customized for single-fibre recordings may also be appropriate to clarify the recruitment properties of single motor units as well as the spatial distribution of such recruitment throughout a muscle, although such single-fibre recordings were not used here. Such experiments would address aspects of descending motor control that cannot be addressed via the multi-unit sampling obtained from chronically-implanted bipolar hook electrodes.

Acute recording techniques could also be used in a prospective fashion to screen the recruitment of a series of muscles in a given task, in order to identify targets suitable for a chronic implant. For example, the neck muscles spanning the cardiothoracic junction have not been well studied in the primate, despite evidence from cineradiographic studies that stress the importance of this region in the control of vertical head posture and motion (Graf et al.,

1995; Vidal et al., 1986). Targeting this region first with acutely-inserted electrodes may help optimize the implantation strategy for chronic approaches.

There is an extensive literature describing the clinical value of needle EMG in humans, including for the diagnoses of pathologies of the upper neck (Daube and Rubin, 2009; So, 1999). While needle EMG is a safe procedure, potential but rare complications include transient discomfort, bruising, bleeding and infection. The use of ultrasonography (enabling visualization of large vessels) and sedation can lessen some of these concerns. However, the impact of repeated insertions of needle EMG electrodes into the deep muscles of the upper neck, as would be required for experiments sampling single motor units sequentially or pairing EMG and neurophysiological techniques, is not known. Repeated insertions of needle EMG electrodes into the limb muscles of awake monkeys are well tolerated and not associated with any adverse effects (Kurtzer et al., 2006). One of our future goals will be to establish the reproducibility and long-term safety of this procedure in the upper neck.

Although we described the acute insertion of EMG electrodes, ultrasound-guided techniques could easily be applied to other experiments targeting the upper neck. For example, transneuronal tracers such as the rabies virus (Kelly and Strick, 2000; Ugolini, 2010) have recently been injected into primate eye muscles to trace oculomotor circuits (Ugolini et al., 2006). Ultrasonography could be used to guide the injection of similar agents into the suboccipital neck muscles to trace cephalomotor circuits, particularly since such muscles appear to form the core of the horizontal head turning synergy (Corneil et al., 2001). Ultrasound-guidance could also be used to inject agents to temporarily anesthetize the muscles of the deep neck, which has been shown to produce gross deficits in motor control resembling vestibular lesions (Cohen, 1961; de Jong et al., 1977). In any such experiment, it would be imperative to ensure that the needle tip is localized in the appropriate target before injection. We can foresee that such experiments would use 'injectrodes' similar to those used for the injection of pharmaceutical agents into the brain (Chen et al., 2001; Crist et al., 1988), delivering threshold stimulation directly to the muscle (which, as we showed here, is visible with ultrasonography) to ensure localization prior to injections.

We also paired a simple and rapidly reversible sedation technique with EMG recordings from a recovered animal. Insertion of homonymous muscles in humans can be done without sedation (Bexander et al., 2005; Blouin et al., 2007), although this requires subject compliance. The use of an experimental animal necessitates sedation to avoid undue distress and strain on the implant, but the level of sedation may well depend on both experimental and idiosyncratic factors. At the level of sedation used here, we did not observe any adverse responses to what is effectively a deep intramuscular injection with a small gauge cannula (considerably smaller than that used to draw blood). Future variations of this technique may explore whether lighter planes of sedation are sufficient, or use a sedation technique that is completely reversible (e.g., medetomidine alone followed by complete reversal via atipamazole). The latter technique would avoid lingering and tolerance-related effects of ketamine, and would be suitable if the animal is required to perform a more complex behavioural task across multiple days. Given the individual nature of the animals, there may be a need to tailor the sedative requirements to the individual's behaviour and pain tolerance.

In conclusion, the approach presented here provides a relatively simple means for accessing a complex area, complementing chronic approaches that require an invasive surgery. The choice of a particular EMG recording approach (e.g., acute versus chronic, single versus multiple motor unit), as well as the sedative requirements, will ultimately be dictated by the desired goal of a particular experiment.

Acknowledgement

This work was supported by an operating Grant from the Canadian Institutes of Health Research (CIHR MOP 93796).


Appendix A. Supplementary data

Supplementary data associated with this article can be found, in the online version, at doi:10.1016/j.jelekin.2012.02.014.

References

- André-Deshays C, Berthoz A, Revel M. Eye-head coupling in humans. I. Simultaneous recording of isolated motor units in dorsal neck muscles and horizontal eye movements. *Exp Brain Res* 1988;69:399–406.
- Angelaki DE, Cullen KE. Vestibular system: the many facets of a multimodal sense. *Annu Rev Neurosci* 2008;31:125–50.
- Bakker DA, Richmond FJ. Muscle spindle complexes in muscles around upper cervical vertebrae in the cat. *J Neurophysiol* 1982;48:62–74.
- Bexander CS, Mellor R, Hodges PW. Effect of gaze direction on neck muscle activity during cervical rotation. *Exp Brain Res* 2005;167:422–32.
- Blouin JS, Siegmund GP, Carpenter MG, Inglis JT. Neural control of superficial and deep neck muscles in humans. *J Neurophysiol* 2007;98:920–8.
- Bogduk N, Govind J. Cervicogenic headache: an assessment of the evidence on clinical diagnosis, invasive tests, and treatment. *Lancet Neurol* 2009;8:959–68.
- Chapman BB, Corneil BD. Neuromuscular recruitment related to stimulus presentation and task instruction during the anti-saccade task. *Eur J Neurosci* 2011;33:349–60.
- Chen LL, Goffart L, Sparks DL. A simple method for constructing microinjectrodes for reversible inactivation in behaving monkeys. *J Neurosci Methods* 2001;107:81–5.
- Cohen LA. Role of eye and neck proprioceptive mechanisms in body orientation and motor coordination. *J Neurophysiol* 1961;24:1–11.
- Cooper S, Daniel PM. Muscle spindles in man; their morphology in the lumbricals and the deep muscles. *Brain* 1963;86:563–86.
- Corneil BD, Munoz DP, Chapman BB, Admans T, Cushing SL. Neuromuscular consequences of reflexive covert orienting. *Nat Neurosci* 2008;11:13–5.
- Corneil BD, Olivier E, Munoz DP. Neck muscle responses to stimulation of monkey superior colliculus. I. Topography and manipulation of stimulation parameters. *J Neurophysiol* 2002;88:1980–99.
- Corneil BD, Olivier E, Munoz DP. Visual responses on neck muscles reveal selective gating that prevents express saccades. *Neuron* 2004;42:831–41.
- Corneil BD, Olivier E, Richmond FJ, Loeb GE, Munoz DP. Neck muscles in the rhesus monkey. II. Electromyographic patterns of activation underlying postures and movements. *J Neurophysiol* 2001;86:1729–49.
- Crist CF, Yamasaki DS, Komatsu H, Wurtz RH. A grid system and a microsyringe for single cell recording. *J Neurosci Methods* 1988;26:117–22.
- Daube JR, Rubin DI. Needle electromyography. *Muscle Nerve* 2009;39:244–70.
- de Jong PT, de Jong JM, Cohen B, Jongkees LB. Ataxia and nystagmus induced by injection of local anesthetics in the Neck. *Ann Neurol* 1977;1:240–6.
- Elsley JK, Nagy B, Cushing SL, Corneil BD. Widespread presaccadic recruitment of neck muscles by stimulation of the primate frontal eye fields. *J Neurophysiol* 2007;98:1333–54.
- Falla D, Jull G, Dall'Alba P, Rainoldi A, Merletti R. An electromyographic analysis of the deep cervical flexor muscles in performance of craniocervical flexion. *Phys Ther* 2003;83:899–906.
- Falla D, Jull G, O'Leary S, Dall'Alba P. Further evaluation of an EMG technique for assessment of the deep cervical flexor muscles. *J Electromyogr Kinesiol* 2006;16:621–8.
- Falla DL, Jull GA, Hodges PW. Patients with neck pain demonstrate reduced electromyographic activity of the deep cervical flexor muscles during performance of the craniocervical flexion test. *Spine (Phila Pa 1976)* 2004;29:2108–14.
- Graf W, De WC, Vidal PP, Wang DH, Evinger C. The orientation of the cervical vertebral column in unrestrained awake animals. II. Movement strategies. *Brain Behav Evol* 1995;45:209–31.
- Isa T, Sasaki S. Brainstem control of head movements during orienting: organization of the premotor circuits. *Prog Neurobiol* 2002;66:205–41.
- Kamibayashi LK, Richmond FJ. Morphometry of human neck muscles. *Spine* 1998;23:1314–23.
- Kelly RM, Strick PL. Rabies as a transneuronal tracer of circuits in the central nervous system. *J Neurosci Methods* 2000;103:63–71.
- Kulkarni V, Chandry MJ, Babu KS. Quantitative study of muscle spindles in suboccipital muscles of human fetuses. *Neurol India* 2001;49:355–9.
- Kurtzer I, Pruszynski JA, Herter TM, Scott SH. Primate upper limb muscles exhibit activity patterns that differ from their anatomical action during a postural task. *J Neurophysiol* 2006;95:493–504.
- Lestienne FG, Le Goff B, Liverneaux PA. Head movement trajectory in three-dimensional space during orienting behavior toward visual targets in rhesus monkeys. *Exp Brain Res* 1995;102:393–406.
- Mayoux-Benhamou MA, Revel M, Vallee C. Surface electrodes are not appropriate to record selective myoelectric activity of splenius capitis muscle in humans. *Exp Brain Res* 1995;105:432–8.

- McCluskey MK, Cullen KE. Eye, head, and body coordination during large gaze shifts in rhesus monkeys: movement kinematics and the influence of posture. *J Neurophysiol* 2007;97:2976–91.
- Populin LC. Monkey sound localization: head-restrained versus head-unrestrained orienting. *J Neurosci* 2006;26:9820–32.
- Rezvani S, Corneil BD. Recruitment of a head-turning synergy by low-frequency activity in the primate superior colliculus. *J Neurophysiol* 2008;100:397–411.
- Richmond FJ, Corneil BD, Singh K. Animal models of motor systems: cautionary tales from studies of head movement. *Prog Brain Res* 1999a;123:411–6.
- Richmond FJ, Corneil BD, Vernon H. Afferent mechanisms in the upper cervical spine The Cranio-cervical syndrome: Mechanisms, assessment and treatment. Oxford: Butterworth-Heinemann; 2001a.
- Richmond FJ, Singh K, Corneil BD. Marked non-uniformity of fiber-type composition in the primate suboccipital muscle obliquus capitis inferior. *Exp Brain Res* 1999b;125:14–8.
- Richmond FJ, Singh K, Corneil BD. Neck muscles in the rhesus monkey. I. Muscle morphometry and histochemistry. *J Neurophysiol* 2001b;86:1717–28.
- Richmond FJ, Thomson DB, Loeb GE. Electromyographic studies of neck muscles in the intact cat. I. Patterns of recruitment underlying posture and movement during natural behaviors. *Exp Brain Res* 1992;88:41–58.
- Shinoda Y, Sugiuchi Y, Izawa Y, Hata Y. Long descending motor tract axons and their control of neck and axial muscles. *Prog Brain Res* 2006;151:527–63.
- So YT. Guidelines in electrodiagnostic medicine. Practice parameter for needle electromyographic evaluation of patients with suspected cervical radiculopathy. *Muscle Nerve Suppl* 1999;8:S209–21.
- Ugolini G. Advances in viral transneuronal tracing. *J Neurosci Methods* 2010;194:2–20.
- Ugolini G, Klam F, Doldan DM, Dubayle D, Brandi AM, Buttner-Ennever J, et al. Horizontal eye movement networks in primates as revealed by retrograde transneuronal transfer of rabies virus: differences in monosynaptic input to “slow” and “fast” abducens motoneurons. *J Comp Neurol* 2006;498:762–85.
- Vidal PP, Graf W, Berthoz A. The orientation of the cervical vertebral column in unrestrained awake animals. I. Resting position. *Exp Brain Res* 1986;61:549–59.



Tyler R. Peel obtained his B.M.Sc in Pharmacology and Toxicology at the University of Western Ontario in 2009. He is currently a Ph.D. candidate in the Neuroscience Graduate Program at the same university under the supervision of Dr. Corneil. His research interests include the influence of cryogenic inactivation of the primate frontal eye fields on oculomotor behaviour and neural activity within the superior colliculus. He is currently supported by a Queen Elizabeth II Graduate Scholarship in Science and Technology.



Katherine A. Green, RVT, graduated from St. Clair College (Windsor Campus, Windsor, Canada) in 1999 with a diploma as a Veterinary Technician. She obtained registration with the Ontario Association of Veterinary Technicians later the same year. She then worked in clinical practice before transitioning to research in 2003. She joined Dr. Corneil in 2009 as a research technician and laboratory manager. Her specific interests include animal husbandry, enrichment, and ultrasonography.



Brian D. Corneil, Ph.D. is an Associate Professor in the Departments of Physiology & Pharmacology, and Psychology at the University of Western Ontario, and a Scientist at the Robarts Research Institute. He received his Ph.D. in 2001 in Physiology at Queen's University in Canada, and was a post-doc at the California Institute of Technology from 2001 to 2003. His research, which combines neurophysiological and behavioural techniques in both humans and animals, addresses the neural control of accurate movement with a particular focus on the coordination of eyes and head movements during rapid gaze shifts. His research is currently supported by the Canadian Institutes of Health

Research and the Natural Sciences and Engineering Research Council of Canada.



Ian D. Welch, DVM, Dipl. Path. graduated from the Ontario Veterinary College in 1992. After 10 years in practice he joined the Department of Animal Care and Veterinary Services (ACVS) at the University of Western Ontario. In 2003 he trained in microsurgery in the Department of Experimental Surgery at the London Health Research Institute. In 2006 he graduated with a diploma in Laboratory Animal Pathology from The Department of Pathobiology at the University of Guelph. Currently he is an Assistant Director at ACVS focusing on research support and development.



Samantha C. Goonetilleke, Ph.D. obtained a B.Psych in 2003 and her Ph.D. in 2007, both from the University of Sydney. From 2007 to 2011, she worked as a post-doctoral research fellow with Dr. Corneil at the University of Western Ontario, studying neck muscle recruitment in humans following transcranial magnetic stimulation of the frontal eye fields. Currently, she works as a post-doctoral research fellow at the Sensorimotor Physiology Laboratory at the University of British Columbia, Canada, investigating neck muscle involvement in whiplash.